

Tauopathies: recent insights into old diseases

André Delacourte

Inserm Research Director, Lille cedex France

Folia Neuropathol 2005; 43 (4):

Abstract

Neurofibrillary tangles are brain lesions that have been discovered at the beginning of the 20th century, using histological silver staining. Tangles are intra-neuronal hallmarks of a degenerating process: neurofibrillary degeneration (NFD). The basic component involved in tangle formation is tau protein. Tangles are found in more than 20 different neurodegenerative disorders, suggesting that NFD is a unique consequence to different types of etiological factors. However, tangles have a morphological and biochemical signature which is disease-specific. They are made up of different types of filaments such as paired helical filaments (PHFs) in Alzheimer's disease or straight filaments in progressive supranuclear palsy. Tau aggregates have a disease-specific biochemical bar-code due to the aggregation of specific sets of tau isoforms. Tau lesions have also a disease-specific pattern of spatio-temporal progression in the human brain which is well correlated to cognitive impairment. At last, pathological tau mutations are at the origin of familial fronto-temporal diseases with parkinsonism (FTDP-17). Together, these observations have generated the concept of tauopathies. Indeed, each tauopathy is defined by a combination of clinical, neuropathological, biochemical and genetic features. Most of them have a specific defect on tau (mutation, aberrant splicing, abnormal phosphorylation, abnormal processing, neuronal or genotypic vulnerability), suggesting that, in fact, the etiology of most tauopathies is directly linked to tau dysfunction. In conclusion, we observe that most dementing disorders are tauopathies and that most demented patients have a tauopathy.

Key words: ???

Introduction

Neurodegenerative disorders have been mostly described and characterized at the turn of the 19th century. Their description, based upon a combination of clinical and neuropathological features, is solid and will never change. In these last 25 years, molecular analysis of brain lesions and genetic studies have brought clues on the etiological mechanisms. From these new molecular findings new concepts have emerged such as the

tauopathies, synucleopathies, amyloidopathies, proteinopathies. However, from the same bulk of hard data, different and even opposite ideas are proposed. For example, is Alzheimer's disease an amyloidopathy, a tauopathy or anything else? The good answer to this question will lead to an efficient therapeutic approach. This article will review the transformation of ideas around an old lesion observed in numerous diseases: neurofibrillary tangles.

Communicating author:

André Delacourte, Inserm Research Director, Inserm Unit 422, 1, Place de Verdun, 59045 Lille cedex France, e-mail: andre.delacourte@lille.inserm.fr

Tangles are found in numerous diseases

Most neurodegenerative disorders are characterized by specific brain lesions. These lesions have been demonstrated at the beginning of the 20th century at the histological level, using different stains. One of them, the silver staining, used with different protocols (Bodian, Gallyas, Bielschowsky, Palmgrem) [1] was an excellent tool to reveal the so-called "tangles", the markers of a degenerating process: neurofibrillary degeneration.

Using these stains, neuropathologists have been able to detect tangles in different clinical entities, that are now well defined such as Alzheimer's disease (AD), Down syndrome (DS) [2], Pick's disease (PiD), Progressive supranuclear palsy (PSP) [3], corticobasal degeneration (CBD), fronto-temporal dementia with parkinsonism linked to chromosome 17 (FTDP-17), myotonic dystrophy, subacute sclerosing panencephalitis, post-encephalic parkinsonism, dementia pugilistica, Niemann-Pick disease type C [4], Hallervorden-Spatz disease [5].

There are different brands of tangles

Because tangles were found in numerous and very different diseases, it was logical to conclude that neurofibrillary degeneration was a unique neuronal response to different types of aggression, and therefore a consequence, not a cause [6].

However, electron microscope observations revealed that all tangles are not the same. Indeed, they are composed of bundles of paired-helical filaments (PHF) in AD, while they are made up to straight filaments in PSP [7,8] and random filaments in PiD [9]. Biochemical studies will explain later on these structural differences.

Tau is the basic component of tangles

The molecular area of neurodegenerative disorders started in 1984 and 1985, with the discovery of A β peptide as the basic component of amyloid plaques [10] and microtubule associated protein tau as the basic component of tangles [11,12,13,14].

Rapidly, using antibodies against tau proteins, it has been demonstrated that all types of tangles found in brain diseases were labeled by antibodies against PHF or tau proteins [15]. From these observations the obvious following question was: why are these tau proteins involved in neurodegeneration?

What do we know about these tau proteins?

Neurons, like all other cells, have a cytoskeleton made up of different types of filaments: microtubules, neurofilaments, actin filaments. Microtubules are especially abundant in the axoplasm. They have a role in the three-dimensional organization of the axoplasm as well as in the transport of cargo-vesicles, from the cell body towards nervous endings. Cargo-vesicles contain the biological material (proteins, enzymes) for the replacement of aging structures and for the neuronal activity of nervous endings.

Microtubules are labile structures that are stabilized by tau-tubulin interactions. Tau has two ways to control microtubule stability: the first one is according to its state of phosphorylation, with an increase of phosphorylation that favors the depolymerization of microtubules; the second one is via specific tau isoforms. There are 6 isoforms due to an alternative splicing of exons 2, 3 and 10 [16]. Three isoforms are with 3 repeated binding domains to microtubules (3R), and 3 isoforms with 4 binding domains (4R) in the carboxy-terminal part of the protein. 4R tau isoforms stabilize better microtubules.

Altogether, indirectly, tau proteins are important proteins in that they control microtubule stability, and therefore the intraneuronal transport of cargo-vesicles.

Tau are modified in AD

Using immunohistochemical and biochemical means, it has been demonstrated that tau are modified in AD and in many other degenerative disorders.

The first dysfunction suggested was abnormal phosphorylation, as demonstrated using tau1, a monoclonal antibody against tau that labeled better tangles after their dephosphorylation by alkaline phosphatase [17]. This was further corroborated by western blotting: a triplet of abnormal tau species, with a higher molecular mass (tau 60, 64, 68 according to their molecular weight), are specifically detected in Alzheimer brains. After dephosphorylation, these abnormal tau species recover their normal mass, between 55 and 64 kDa [18,19]. 2D gels and mass spectra analyses confirmed that Alzheimer tau are more phosphorylated [20,21], and therefore more acidic on 2D gels [22]. A fourth abnormal tau component was discovered later on, of 74 kDa [23]. From these results, it was concluded that abnormal phosphorylation was responsible for the collapse of

microtubules, and was the initiator of tau aggregation. The six tau isoforms are involved in the PHF structure [23,24].

From tau to tauopathies: the code-bar of tauopathies

In neurodegenerative disorders with tangles other than Alzheimer's disease, comparative biochemistry of Tau aggregates shows that they differ in both phosphorylation and content of tau isoforms, which enables a molecular classification of tauopathies [25].

Five classes of tauopathies have been defined depending on the type of Tau aggregates that constitute the «Bar Code» for neurodegenerative disorders [16].

Class I: a major Tau triplet at 60, 64, 68/69 kDa

Class I is characterized by a pathological tau triplet at 60, 64 and 69 kDa and a minor pathological tau at 72/74 kDa. It is now well established that this pathological tau triplet corresponds to the aggregation of the six tau isoforms [20,23]. The prototypical neurological disorder that characterizes this class is Alzheimer's disease, but includes additional neurological disorders such as amyotrophic lateral sclerosis parkinsonism-dementia complex of Guam, Parkinsonism with dementia of Guadeloupe, postencephalitic parkinsonism, dementia pugilistica, Down syndrome, Niemann-Pick disease of type C, Familial British dementia as well as fronto-temporal dementia with parkinsonism linked to chromosome 17 (FTDP-17) (reviewed in [26]). This type of tauopathy is also systematically found in the entorhinal formation of people aged over 75 years, and frequently found in addition in the hippocampal formation, with or without amyloid deposition [27].

Class II: a major Tau doublet at 64 and 69 kDa and the concept of 4R tauopathies

The class II profile is characterized essentially by the aggregation of 4R-Tau isoforms. This pathological tau profile is observed in progressive supranuclear palsy (PSP), corticobasal degeneration (CBD), argyrophilic grain (AGD) and frontotemporal dementia with parkinsonism linked to chromosome 17 (FTDP-17) [28,29].

Progressive supranuclear palsy. Progressive supranuclear palsy (PSP) is a late-onset atypical

parkinsonism disorder described by Steele, Richardson, and Olszewski in 1964 [30]. Dementia is also a common feature at the end-stage of the disease [31,32]. Neuropathologically, PSP is characterized by neuronal loss, gliosis and NFT formation. Neurofibrillary tangles were first described in the basal ganglia, brain stem, and the cerebellum [3]. Later on, the degenerating process has been described in the perirhinal, inferior temporal and prefrontal cortex, with the same features as the subcortical NFT [33,34]. Glial fibrillary tangles are also described [35]. Biochemical studies show that aggregated tau in PSP is widely distributed in the subcortical and neocortical areas, but with a major involvement of the subcortico-frontal neuronal networks [36].

Corticobasal degeneration. Corticobasal degeneration (CBD) was first described in 1967 and referred to as corticodentatonigral degeneration with neuronal achromasia [37]. It is a rare, sporadic and slowly progressive late-onset neurodegenerative disorder. It is clinically characterized by cognitive disturbances and extrapyramidal motor dysfunction. Moderate dementia emerges sometimes late in the course of the disease [38]. There is a clinical and pathological overlap between PSP and corticobasal degeneration [39] (31, 40). Neuropathological examination reveals severe glial and neuronal abnormalities. The glial pathology is constituted of astrocytic plaques and numerous tau-immunoreactive inclusions in the white matter while the one in PSP is characterized by tufted plaques. Achromatic ballooned neurons are detected in the cortex, brainstem, subcortical structures as well as neuritic changes and NFT. In both PSP and CBD, the pathological tau profile consists essentially of the aggregation of 4R-Tau isoforms [29]. The neocortical mapping of tau pathology in CBD is similar to PSP [41].

Argyrophilic grain disease. In 1987, Braak and Braak [42] reported a series of eight patients with a non-Alzheimer, late onset dementia. Clinically, argyrophilic grain disease (AGD) fits with the clinical spectrum that is reported: behavioural disturbances such as personality change and emotional imbalance, memory and cognitive impairment [43]. At the neuropathological level, AGD is characterized by the occurrence of argyrophilic grains (ArG) on light microscopy of the brain tissue, and therefore

referred to as Argyrophilic Grain Dementia (AGD). ArGs are neuronal inclusions stained by silver dyes [42]. The diagnosis of dementia with ArGs is based on widespread occurrence of minute, spindle or comma-shaped, argyrophilic, tau-immunoreactive structures distinct from neuropile threads and predominantly located in the hippocampus and related limbic areas [44]. The 4R/3R ratio has been shown to be increased in AGD, thus demonstrating that AGD is most likely a 4R-Tau pathology [45,46]. The tau pathology affects essentially the limbic system but, more recently, the tau pathology has been shown to extend in some cases toward all cerebral cortex, very distant from the limbic temporal region, in brain areas that are considered to be spared in AGD [47]. Many features are shared by all four repeat tauopathies. For example, like in PSP and CBD, the subthalamic nuclei are selectively involved by tau aggregates in AGD patients [48]. The H1/H1 haplotype is more frequent in PSP/CBD patients than in controls or other tauopathies [49]. H1/H1 may be more frequent in AGD patients than in controls, though recent studies have failed to establish statistically a significant difference [50,51].

Class III: a major Tau doublet at 60 and 64 kDa and the concept of 3R tauopathies

This class of tauopathy includes a single neurological disorder that is Pick's disease (PiD). Pick's disease is a rare form of neurodegenerative disorder characterized by a progressive dementing process. Early in the clinical course, patients show signs of frontal disinhibition [52]. Neuropathologically, Pick's disease is characterized by prominent fronto-temporal lobar atrophy, gliosis, severe neuronal loss, ballooned neurons and the presence of neuronal inclusions called Pick bodies [53]. Pick bodies are labeled by tau antibodies, with a higher density in the hippocampus than in the neocortex [54]. The laminar distribution of Pick bodies is clearly different from other tauopathies such as PSP and CBD. In the hippocampus, Pick bodies are numerous in granular cell neurons of the dentate gyrus, in CA1, subiculum and entorhinal cortex, whereas in the neocortex, they are mainly found in layers II and VI of the temporal and frontal lobes. Ultrastructurally, Pick bodies consist of accumulation of both random coiled and straight filaments. The biochemical analysis using a quantitative Western blot approach with phosphorylation-dependent anti-tau antibodies

has revealed that in all cases of PiD studied, a major 60- and 64-kDa pathological Tau doublet is observed in the isocortex, in the limbic areas and in the subcortical nuclei [55,56]. A faint pathological tau band is observed at 69 kDa [57]. The specific pathological tau profile of PiD is due to the aggregation of 3R-Tau isoforms [58]. In addition, aggregated tau proteins in Pick's disease are not detected by the monoclonal antibody 12E8 raised against the phosphorylated residue Ser262/Ser356 whereas in other neurodegenerative disorders, this phosphorylation site is detected [56, 59]. The lack of phosphorylation at Ser262 and -356 sites is likely to be related to either a kinase inhibition in neurons that degenerate in Pick's disease or an absence of these kinases within degenerating neurons [60]. The biochemical mapping of tauopathy in PiD is preferentially in the fronto-temporal regions, as shown at the clinical and neuropathological levels. However, some cases were observed with also a strong involvement of the parietal cortex.

Class IV: a major Tau 60

Class IV is also represented by a single neurological disorder: Myotonic dystrophy of type I. Myotonic dystrophy (DM) is the commonest form of adult-onset muscular dystrophy. It is a multisystemic disease affecting many systems as well as the central nervous system (cognitive and neuropsychiatric impairments), thus leading to a wide and variable complex panel of symptoms [61]. At the clinical level, DM includes two entities designated as myotonic dystrophy of type I (DM1) and myotonic dystrophy of type II (DM2) [62]. DM1, the commonest form of DM, is an inherited autosomal dominant disorder caused by a single gene mutation consisting of expansion of a CTG trinucleotide motif in the 3'V untranslated of the myotonic dystrophy protein kinase gene (*dmpk*), located on chromosome 19q [63]. Neuropathological lesions, such as neurofibrillary tangles, have been observed in adult DM1 individuals aged over 50 years [64, 65]. The pathological tau profile of DM1 is characterized by a strong pathological tau band at 60 kDa and, to a lesser extent, a pathological tau component at 64 and 69 kDa. This typical pathological tau profile is reflected by a reduced number of tau isoforms expressed in the brain of individuals with DM1, both at the protein and mRNA levels [66]. In addition, tau protein expression is also demonstrated to be altered in transgenic with

human DM1 locus [67]. The analysis of multiple brain regions of one genetically confirmed DM2 patient aged 71 years showed some neurofibrillary degenerating processes. Using specific immunological probes against exon 2 and exon 3 corresponding amino acid sequences, the neurofibrillary lesions were shown to be devoid of tau isoforms with N-terminal inserts [66]. An altered splicing of tau characterized by a reduced expression of tau isoforms containing the N-terminal inserts characterizes both DM1 and DM2. Overall, it demonstrates that the central nervous system is affected and that DM are real tauopathies.

Tangles in familial diseases: FTDP-17

In 1994, Wilhelmsen and colleagues have described an autosomal dominantly inherited disease related to familial FTD, characterized by adult-onset behavioral disturbances, frontal lobe dementia, parkinsonism and amyotrophy. They demonstrated a genetic linkage between this pathology, denominated disinhibition-dementia-parkinsonism-amyotrophy complex (DDPAC), and chromosome 17q21–22 [68]. Since then, several families sharing strong clinical and pathological features and for which there is a linkage with chromosome 17q22–22 have been described [69,70,71,72]. They have been included in a group of pathologies referred to as frontotemporal dementia with parkinsonism linked to chromosome 17 (FTDP-17) [73]. Although a clinical heterogeneity could be described, between and within the families with FTDP-17, the usual symptoms include behavioural changes, loss of frontal executive functions, language deficit and hyperorality. Parkinsonism and amyotrophy are described in some families, but are not consistent features. Neuropathologically, brains of FTD patients exhibit an atrophy of the frontal and temporal lobes, a severe neuronal cell loss, a grey and white matter gliosis, and a superficial laminar spongiosis. One of the main important characteristics is the filamentous pathology affecting the neuronal cells, or both neuronal and glial cells in some cases. The absence of amyloid aggregates is usually established [73,74,75].

For a long time, it was unclear whether the aggregation of tau protein follows disease or whether disease follows tau dysfunction. This was resolved when mutations in Tau were found to cause FTDP-17 [75,76,77]. Tau mutations always segregate with the pathology and are not found in the control

subjects, demonstrating their pathogenic role. To date, 35 mutations have been described in the Tau gene in over 100 families.

Mutations observed reduce the ability of tau protein to interact with microtubules and increase its propensity to assemble into abnormal filaments. The other mutations have their primary effect at the RNA level and perturb the normal ratio of three-repeat to four-repeat tau isoforms. All the mutations and their potential pathological effects are described in [16,78,79].

Transgenic models of FTDP-17 have been set up. Mice with mutated tau gene reproduce well clinical and neuropathological features of this disease [80,81,82]. Surprisingly, transgenic mice with overexpression of the normal human tau gene do not reproduce a tau pathology [83,84].

Is neurofibrillary degeneration of sporadic diseases a cause or a consequence?

In 1998, the demonstration of mutations on the tau gene involved in the autosomal dominant form of FTDP 17 demonstrated clearly that tau genetic dysfunction was an etiological factor. But what about sporadic tauopathies, and specially AD, the most studied neurodegenerative disorder. This disease is unique with its two types of brain lesions: tangles and plaques. For researchers it was obvious that determining which lesion comes first was instrumental to determine the cause of the disease.

a) APP is central in AD etiology. After the discovery of Glenner and Wong in 1984, showing that amyloid plaques are made up of a polypeptide of 39 to 42 amino-acids, successively named A4 then Abeta, a number of great discoveries have shown the importance of physiological events linked to plaques [85]. Indeed, the amyloid protein precursor APP was characterized, as well as its gene on chromosome 21 in 1987, by Kang et al, as well as other teams [86]. In 1991, the discovery by John Hardy's team of the first mutations located on APP gene and responsible for familial AD has been a revolution [87]. The cause of AD was known! Other mutations on APP, located at the extremities of A β sequence, reinforced the concept of A β as central to the etiology, such as the Swedish mutation [88]. These data generated the amyloid cascade hypothesis in 1992 [89] with tangle formation

described as one of the latest consequence of neurodegeneration. Other mutations of FAD located on presenilin 1 and 2 by St Georges Hyslop's team corroborated this cascade hypothesis. Indeed, presenilin cleaves APP and PS1 mutations release more A β 42 species [90]. Then transgenic mice with mutated genes on human app and ps1, developing numerous plaques as well as a possible cognitive impairment, corroborated the hypothesis of John Hardy [91]. Nowadays, all scientists agree that APP dysfunction plays a major role in AD etiopathogenesis.

Legitimately, from the amyloid cascade hypothesis, one can conclude that AD is a simple brain disease, with a unique killer, the neurotoxic A β peptide, and a unique and simple therapeutic target: the removal or the neutralization of A β aggregates. Most of AD public and private research has embarked on this theory. But the cascade hypothesis that considers tangles as byproducts coming at the last stage of the disease is based upon a fragile argumentation. Indeed, the accumulation of data on neurofibrillary degeneration have progressively changed the Alzheimer landscape and even more, our perception of the physiopathology of most dementing neurodegenerative disorders.

b) The Braak stages. Heiko Braak is a German neuropathologist that has observed both lesions, plaques and tangles, at the spatio-temporal level. Using silver staining on large tissue sections of several thousands of brains of patients at different stages of the pathology, he was able to see that there is a progressive spreading of NFD, along a precise pathway, from the entorhinal and hippocampal formation towards polymodal association then the primary brain regions [92]. Alzheimer dementia is observed when a threshold of tangle density in the association cortical areas is reached, corresponding to stages IV to VI [93].

c) 1997: a pivotal year. The role of tangles to explain Alzheimer dementia was so obvious that the Braak stages were incorporated in the consensus criteria for a definite diagnosis of AD in 1997 [94]. Strangely enough, the criteria for a definite diagnosis before 1997 were simply wrong. In fact Katchaturian [95] and CERAD criteria [96], that take only into account the number of amyloid plaques, cannot by themselves make a difference between infraclinical and clinical dementia, since the number of plaques can be very important before dementia. Furthermore,

at that time and using CERAD criteria, dementia with Lewy bodies, that has also numerous amyloid plaques, was diagnosed most of the time as AD, since Lewy bodies were not easily detected. Indeed, the detection of Lewy bodies has really been possible with antibodies against their basic component, alpha-synuclein, commercially available after 1997 [97].

In short, the consensus definition of AD in 1997 went back to the sound 1907 definition of Alois Alzheimer: the disease is characterized by both plaques and tangles, and both lesions have to be detected in polymodal association areas in great numbers to justify a definite diagnosis of Alzheimer dementia [94].

d) The spatio-temporal biochemical pathway of tau pathology in aging and sporadic AD. The Braak observations at the immunohistochemical level were corroborated at the biochemical level, using abnormal tau as a probe to quantify neurofibrillary degeneration. A prospective and multidisciplinary study of more than 200 cases, including 70 non-demented patients was undertaken. We gathered clinical and neuropathological data, and in parallel studied the presence of neurofibrillary degeneration at the biochemical level, using the triplet of abnormal tau proteins as a marker. In Alzheimer brains, we observed that tau pathology always extends along ten stages, corresponding to ten brain areas that are successively affected. Paired helical filaments (PHF)-tau pathology was systematically found to be present in variable amounts in the entorhinal and hippocampal regions of non-demented patients aged over 75 years. When tau pathology was found in other brain areas, it was always along a stereotyped, sequential, hierarchical pathway. The progression was categorized into ten stages according to the brain regions affected: transentorhinal cortex (S1), entorhinal cortex (S2), hippocampus (S3), anterior temporal cortex (S4), inferior temporal cortex (S5), mid temporal cortex (S6), polymodal association areas (prefrontal, parietal inferior, temporal superior) (S7), unimodal areas (S8), primary motor (S9a) or sensory (S9b, S9c) areas, and all neocortical areas (S10) [98].

e) Lessons given by tau staging

1. Relationship with Braak staging. Together, there is a perfect agreement on the pathway of progression of the degenerating process described by Braak, ranked from stage I to VI at the histochemical level,

and our staging at the biochemical level. Surprisingly, our biochemical approach was more precise than the neuropathological one, in that we observed precisely that the temporal pole was affected just after the hippocampus and prior to the inferior temporal cortex. This step is included in our staging. Also we were able to distinguish a transentorhinal stage prior to the entorhinal stage and then to the hippocampal stage, showing that the scalpel can also make the approach very precise.

2. Relationship with aging. At the present time, we have probably studied more than 500 patients comprising non-demented patients and demented patients with different neurodegenerative brain diseases, with the exception of prion diseases. First we observed that all patients aged over 75 years, controls or those affected by a brain pathology, had at least a tau pathology in the entorhinal formation, and very frequently in the hippocampal formation. Since 100% of patients have a tau pathology at the age of 75 years, this means that tau pathology is an inevitable degenerating process in humans. This vulnerability to tau pathology in the entorhinal and hippocampal formations is also present in a few non-human species such as the baboon or the rhesus monkey [99,100]. Immunohistochemistry is more sensitive than biochemistry to analyze the formation of tau pathology in some specific subsets of neuronal populations. Braak demonstrated that neurofibrillary degeneration can begin very early in the human brain. Using the same histological approach and antibodies against specific tau phosphorylated sites such as ser 199P, we observed similar findings [101]. Together, these studies show that a mild tauopathy is observed in 2 patients out of 10 at the second to third decade of age. At the age of 50 years, probably 1 patient out of 2 has a small but significant entorhinal tau pathology. The frequency increases with age to be constant at the age of 75 years using either histochemical or biochemical means.

From these results one could speculate that entorhinal tau pathology is an age-associated process, but in fact we think it is more a vulnerability that is revealed during aging. Indeed, we have been able to study the brain of non-demented centenarians. A few of these patients were relatively spared, with a very mild entorhinal tauopathy, demonstrating the absence of a direct link with aging.

3. Brain lesion burden in mild cognitive impairment (MCI). There is no clinical method to determine if a patient with MCI has incipient AD. Some will convert to AD, but not all. Our prospective study led us to collect all data on the cognitive status as well as the extent of tau and A β pathology of patients with MCI [98] [102]. We observed that all 13 MCI patients from our brain bank had a tau pathology, but not necessarily an A β pathology. Furthermore, all patients of our prospective study with a mild tau pathology did not have MCI, probably because the tau burden for these patients was compensated by neuronal plasticity. These results are in perfect agreement with those of the Mesulam group [103] showing that a tau pathology is more closely related to cognitive impairment than is A β . However, from our knowledge of A β aggregation in AD (following chapters), we know that the presence of A β deposits in the brain of MCI patients, as well as a decrease of A β x-42 in the CSF [104], is the marker of incipient AD.

4. The threshold for dementia. Another interesting point of our staging of tau pathology is the clinical status of patients at stage 7, with a mild to moderate tau pathology in the polymodal association areas. All of them are cognitively impaired, but at very different levels. Altogether, we observed that the patients that are fully demented at stage 7 have generally in addition a significant vascular pathology. The logical explanation is that a vascular pathology has an additional deleterious effect on neuronal plasticity, that decreases the compensation effect of the not-yet affected neuronal populations, and therefore increases the cognitive deficit. These observations strengthen the idea that clinical impairment results from an imbalance between a progressing degenerating process and decreasing compensatory effects from the not-yet affected neurons. The best illustration comes from Parkinson disease, with extra-pyramidal signs expressed only if more than 50 to 90 % of the dopaminergic neurons are affected.

5. The mechanism of progression of tau pathology. The mechanism of tauopathy spreading is likely to open relevant therapeutic avenues in the neuroprotection domain. From the study of AD, we observe that this spreading is not diffuse, but on the

Table I. Biochemical staging for the quantification of either A β 40 or A β x-42 aggregates

Neocortical A β quantification (μ g/g of tissue)	Stage
From trace to 2.5	1
2.5 to 5	2
5 to 10	3
10 to 25	4
25 to 50	5
50 to 100	6
100 to 200	7
200 to 400	8
400 to 800	9
Over 800	10

contrary along precise neuron-to-neuron connections, from the limbic structures toward the neocortical association areas. Interestingly enough, we observe a similar mechanism of spreading in other sporadic tauopathies, such as progressive supranuclear palsy (PSP). Neurodegeneration in PSP is observed first in the brain stem, then in the striatum, to conquer after the primary motor frontal neocortical area (Brodmann area 4), then the unimodal frontal areas and at last a spreading in all neocortical and limbic areas [29]. In other words, the basic mechanism of tau spreading in sporadic tauopathies is likely starting in a specific vulnerable neuronal population (layer II of the entorhinal formation in AD; oculomotor nuclei for PSP). Then, this local tauopathy will destabilize the connected neuronal populations that had a cross-talk with the vulnerable area, and this degenerating process will extend, with a domino effect, to other neuronal populations along a neuron-to-neuron propagation phenomenon [105]. Knowing better this mechanism of propagation will certainly open therapeutic strategies for AD as well as for other sporadic tauopathies and synucleopathies.

6. The relationship between tauopathy and amyloidosis in aging and sporadic AD. It is not surprising that tau pathology is well correlated with cognitive impairment, since it shows the alteration of neurons and its extent. However, we do not know the factors that generate tauopathy and its

extension in the brain areas. A β PP dysfunction is the best candidate, as revealed by genetic studies. Therefore, we quantified all A β PP metabolic products to see a possible relationship with the different stages of tau pathology. A β PP holoproteins, A β PP-CTFs and A β species were analyzed in the different brain areas of all our non-demented and demented patients. First, A β species were studied. Insoluble A β -42 and -40 species were fully solubilized and quantified after their extraction in pure formic acid. In order to simplify the interpretation of the results, we propose the following biochemical staging for the quantification of either A β 40 or A β x-42 aggregates [102] – table I.

The quantities of both A β species were compared to the extent of tau pathology, as well as to cognitive impairment. A β x-42 aggregates were observed at the early stages of tau pathology in non-demented patients and all along AD pathology (A β stages 1 to 4), while A β x-40 aggregates are markers of the last stages of AD. During the progression of the disease, A β x-42 aggregates increase in quantity and heterogeneity (A β stages 4 to 10), in close parallelism to the extension of tau pathology. But unexpectedly, there was no spatial overlap between A β aggregation that is widespread and heterogeneously distributed in the cortical areas and a tau pathology that is progressing sequentially, stereotypically, and hierarchically. Hence, there is a synergetic effect of APP dysfunction on the neuron-to-neuron propagation of tau pathology (Figure 1). Indeed, a tau pathology can be found in the hippocampal area without A β deposits, as mentioned by Braak [106]. In contrast, the extension of tau pathology in the polymodal association areas was systematically found in the presence of A β deposits (A β stages 4 to 10), as if these A β species, directly or indirectly, were necessary to stimulate the progression of tau pathology. Altogether, our study clearly demonstrated that amyloid deposits do not precede a Tau pathology in sporadic AD, as mentioned in the amyloid cascade hypothesis (devoted to familial AD). Interestingly enough, our proteomic analysis of the first A β 42 deposits that appear in the aging human brain and in incipient AD are not full length A β 1-42, but N-truncated species. In other words, the first A β species that initiate amyloidosis are not physiological species, but pathological species. This was observed at the proteomic and immunohistochemical levels. This discovery could improve dramatically the

vaccination approach since we propose to use the "pathological" antigen to boost the immunoreaction, in order to avoid an auto-immune reaction [107]. Also, our study of A β in 4 neocortical areas showed that the first deposits are not observed in a specific area. Generally the occipital region is the region which is the most prone to develop amyloid deposits. The temporal or the frontal cortex are sometimes affected first. This observation alone demonstrates that if there is a neurotoxicity of A β species, this hypothetic neurotoxic mechanism is certainly not working on the neighboring neurons. Indeed, the occipital region is always the last to degenerate in AD.

Relationship between tau pathology and amyloid precursor protein dysmetabolism

The parallelism and synergy between tau and A β aggregation led us to search an A β PP molecular event linking the two degenerating processes. A β PP is an ubiquitous protein found in all cell types of all species, suggesting a basic and important role that remains to be identified. A neurotrophic activity for A β PP and secreted sA β PP is often mentioned [108]. Therefore a loss of function of A β PP rather than a gain of toxic function of A β , could be also a reasonable

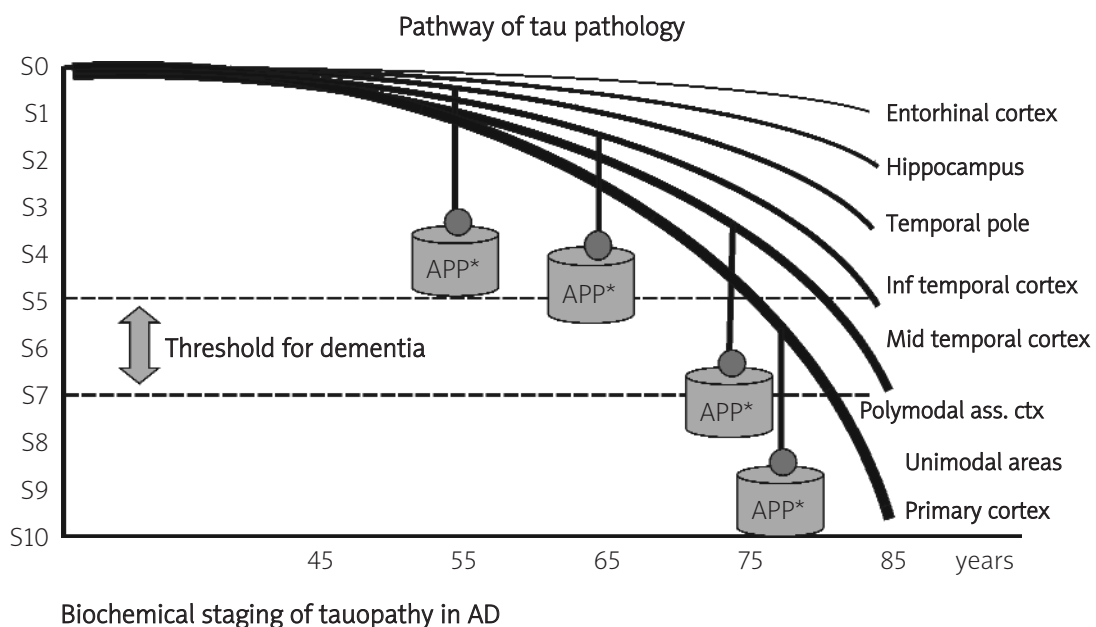


Fig. 1. Scenario for sporadic Alzheimer's disease. First, neurofibrillary tangles (i.e tau pathology) are age-related but not age-dependent lesion. They appear in the entorhinal cortex of 20% of people aged 25 years. The ratio increases at 50% at the age of 50 years to affect all people at the age of 70 years or older. This vulnerability varies dramatically among individuals. A few nonagenarians of our study were very mildly affected. The entorhinal cortex is a vulnerable area always affected by a tau pathology at old age. Second, tauopathy in aging tends to spread from the vulnerable area to other connected neuronal population, along a neuron-to-neuron propagation that resembles a chain reaction or a domino effect. This spreading can be observed up to the temporal pole without A β ?deposition (stage 4 of tau pathology). Third, however, the extension of tauopathy toward the polymodal association areas is only observed in the presence of A β x-42 deposits, as if these aggregates, directly (neurotoxicity) or indirectly (markers of APP dysfunction) were fueling tau spreading. Fourth, the cognitive impairment observed in Alzheimer's disease is well explained by the brain areas that are successively affected by tau pathology. Fifth, when neuroplasticity will be no more able to compensate the progressing neurodegenerative process, clinical impairment and dementia will appear. Sixth, tau pathology will continue its conquest of the brain, toward the primary regions and subcortical areas

hypothesis to explain the stimulation of tau pathology and neurodegeneration.

Complementary to this study of A β species, we found no obvious modification of APP holoprotein in correlation with the pathology. However, A β PP-CTFs were found to be significantly diminished during the course of AD and well correlated with the progression of tau pathology [109]. Beta, alpha and gamma stubs were also significantly decreased in the brain tissue of individuals having an inherited form of AD linked to mutations of presenilin 1, showing a general defect common to familial and sporadic forms of AD. In a way, it is ironic that many big pharmas are trying to decrease the levels of beta stubs to decrease secondarily the production of A β by inhibiting BACE, while in the AD human brain, these fragments are not increased but decreased, and more insoluble. An important role of the gamma stubs (also named AICD (A β PP intracellular domain)) as a gene regulator could explain its involvement in the disease, since these fragments are dramatically reduced in AD [110,111,112].

In fact these observations directly lead to other therapeutic strategies concentrated around the concept of a loss of function of APP stimulating tau pathology, in good agreement with other teams mentioning that A β may be a planet, but A β PP is central [113,114,115]. From our study on tau and A β in the human brain, we propose the following "four hit" hypothesis for a good anti-Alzheimer drug: these drugs should increase the alpha-secretase activity and therefore (1) increase the production of the potential transcription factor AICD, (2) increase in the same mechanism the secretion of sAPP alpha, a potential neurotrophic factor, and subsequently (3) decrease the production of beta stubs and A β , a potential neurotoxic, and (4), the beneficial effects should slow down the progression of tauopathies. Theoretically, this drug should be able to reduce or to stop the deleterious effect of A β PP loss of function, and therefore able to stop the burden that fuels a tau pathology and provoke dementia in AD. Drugs that have this property are already on the bench [116].

An alternative relevant target would be to work directly on tau to stop dementia, bearing in mind that it concerns not only AD, but also 10 to 20 other dementing disorders.

Concluding remarks

Differential vulnerability of brain areas to neurofibrillary degeneration

Tangles are the first visual signs of neurofibrillary degeneration. In sporadic diseases, they always appear first in specific brain areas, demonstrating a focal vulnerability. As already mentioned, this vulnerability is different for AD (entorhinal formation) and PSP or CBD (brain stem). In addition, the type of tauopathy is different (3R+4R in AD, 4R in PSP). We speculated that the bar code of tauopathy in sporadic disease could result from the degeneration of specific subsets of neurons, that express specific sets of tau isoforms [58]. The question is still open.

Vulnerability and sequential progression of the pathology in brain areas is a feature of numerous sporadic degenerative disorders. This is true not only for tauopathies but also for synucleopathies. For familial diseases, we note the same vulnerability through pathogenic mutations on tau and synuclein. This convergence between familial and sporadic diseases on the basic components of lesions demonstrate their etiologic role.

Tangles and the diagnosis of tauopathies

Tangles are histological hallmarks of neurofibrillary degeneration. Theoretically, their presence could also be detected in the CSF, to be used as "biomarkers". Indeed, neurons with tangles die and tangles debris are likely released in the CSF. This is true for AD, and the quantification of tau and P-tau is already possible for the routine analysis. This analysis is a help for the clinician by increasing its specificity and sensitivity [117].

However, despite the clear difference between 3R, 4R or 3+4 R tauopathies, the tau biomarker is not yet useful for the biological diagnosis of diseases other than AD.

Tangles and the treatment of tauopathies

There is accumulating evidence that most dementing disorders are tauopathies and that Alzheimer's disease is a real tauopathy, showing also that most of dementing patients (more than 80%) suffer from a tauopathy. Of course, we note that tauopathies are very heterogeneous and that many different types of tau dysfunction lead to dementia: mutations on the tau gene in FTDP-17

(fronto temporal dementia with Parkinsonism linked to chromosome 17) [118], the haplotype H1H1 which is a risk factor for PSP and CBD [119], the abnormal tau splicing in DM1 [120], tau-less DLDH [121], and the vulnerability of specific brain areas to a tauopathy as observed in the entorhinal cortex and hippocampus for AD [122], or in the brain stem nuclei for PSP and CBD. Therefore, if tau is an excellent therapeutic target, it remains to determine the strategy for each disease. For AD, the more obvious and easy-to-test target is the abnormal phosphorylation. Inhibitors of kinases such as GSK3 β [123] or cdk5 [124] are good candidates. Transgenic mice with tau mutations are also at disposal (<http://www.alzforum.org>). Therefore, a dynamic of drug discovery for tauopathies has emerged. In that perspective, scientists in the field should not forget to model the most obvious human features of tauopathies such as a synergy with APP dysfunction in AD or models that reflect tau spreading in the cortical areas.

References

1. Yamamoto T, Hirano A. A comparative study of modified Bielschowsky, Bodian and thioflavin S stains on Alzheimer's neurofibrillary tangles. *Neuropathol Appl Neurobiol* 1986; 12: 3-9.
2. Wisniewski K, Jervis GA, Moretz RC, Wisniewski HM. Alzheimer neurofibrillary tangles in diseases other than senile and presenile dementia. *Ann Neurol* 1979; 5: 288-294.
3. Jellinger K, Riederer P, Tomonaga M. Progressive supranuclear palsy: clinico-pathological and biochemical studies. *J Neural Transm Suppl* 1980; 111-128.
4. Love S, Bridges LR, Case CP. Neurofibrillary tangles in Niemann-Pick disease type C. *Brain* 1995; 118 (Pt 1): 119-129.
5. Mitsuyama Y, Seyama S. Frequency of Alzheimer's neurofibrillary tangle in the brains of progressive supranuclear palsy, postencephalitic parkinsonism, Alzheimer's disease, senile dementia and non-demented elderly person. *Folia Psychiatr Neurol Jpn* 1981; 35: 189-204.
6. Terry RD. Do neuronal inclusions kill the cell? *J Neural Transm Suppl* 2000; 59: 91-93.
7. Tomonaga M. Ultrastructure of neurofibrillary tangles in progressive supranuclear palsy. *Acta Neuropathol (Berl)* 1977; 37: 177-181.
8. Ghatak NR, Nochlin D, Hadfield MG. Neurofibrillary pathology in progressive supranuclear palsy. *Acta Neuropathol (Berl)* 1980; 52: 73-76.
9. Kato S, Nakamura H, Otomo E. Reappraisal of neurofibrillary tangles. Immunohistochemical, ultrastructural, and immunoelectron microscopical studies. *Acta Neuropathol (Berl)* 1989; 77: 258-266.
10. Wong CW, Quaranta V, Glenner GG. Neuritic plaques and cerebrovascular amyloid in Alzheimer disease are antigenically related. *Proc Natl Acad Sci U S A* 1985; 82: 8729-8732.
11. Brion JP, Flament-Durand J, Dustin P. Alzheimer's disease and tau proteins. *Lancet* 1986; 2: 1098.
12. Delacourte A, Defossez A. Alzheimer's disease: Tau proteins, the promoting factors of microtubule assembly, are major components of paired helical filaments. *J Neurol Sci* 1986; 76: 173-186.
13. Grundke-Iqbal I, Iqbal K, Quinlan M, Tung YC, Zaidi MS, Wisniewski HM. Microtubule-associated protein tau. A component of Alzheimer paired helical filaments. *J Biol Chem* 1986; 261: 6084-6089.
14. Kosik KS, Joachim CL, Selkoe DJ. Microtubule-associated protein tau (tau) is a major antigenic component of paired helical filaments in Alzheimer disease. *Proc Natl Acad Sci U S A* 1986; 83: 4044-4048.
15. Joachim CL, Morris JH, Kosik KS, Selkoe DJ. Tau antisera recognize neurofibrillary tangles in a range of neurodegenerative disorders. *Ann Neurol* 1987; 22: 514-520.
16. Sergeant N, Delacourte A, Buee L. Tau protein as a differential biomarker of tauopathies. *Biochim Biophys Acta* 2005; 1739: 179-197.
17. Grundke-Iqbal I, Iqbal K, Tung YC, Quinlan M, Wisniewski HM, Binder LI. Abnormal phosphorylation of the microtubule-associated protein tau (tau) in Alzheimer cytoskeletal pathology. *Proc Natl Acad Sci U S A* 1986; 83: 4913-4917.
18. Flament S, Delacourte A, Hemon B, Defossez A. Characterization of two pathological tau protein, variants in Alzheimer brain cortices. *J Neurol Sci* 1989; 92: 133-141.
19. Goedert M, Spillantini MG, Jakes R, et al. Molecular dissection of the paired helical filament. *Neurobiol Aging* 1995; 16: 325-334.
20. Goedert M, Spillantini MG, Cairns NJ, Crowther RA. Tau proteins of Alzheimer paired helical filaments: abnormal phosphorylation of all six brain isoforms. *Neuron* 1992; 8: 159-168.
21. Hasegawa M, Morishima-Kawashima M, Takio K, Suzuki M, Titani K, Ihara Y. Protein sequence and mass spectrometric analyses of tau in the Alzheimer's disease brain. *J Biol Chem* 1992; 267: 17047-17054.
22. Sergeant N, Bussiere T, Vermersch P, Lejeune JP, Delacourte A. Isoelectric point differentiates PHF-tau from biopsy-derived human brain tau proteins. *Neuroreport* 1995; 6: 2217-2220.
23. Sergeant N, David JP, Goedert M, et al. Two-dimensional characterization of paired helical filament-tau from Alzheimer's disease: demonstration of an additional 74-kDa component and age-related biochemical modifications. *J Neurochem* 1997; 69: 834-844.
24. Goedert M, Klug A. Tau protein and the paired helical filament of Alzheimer's disease. *Brain Res Bull* 1999; 50: 469-470.
25. Pasquier F, Delacourte A. Non-Alzheimer degenerative dementias. *Curr Opin Neurol* 1998; 11: 417-427.
26. Buee L, Delacourte A. Comparative biochemistry of tau in progressive supranuclear palsy, corticobasal degeneration, FTDP-17 and Pick's disease. *Brain Pathol* 1999; 9: 681-693.
27. Delacourte A, David JP, Sergeant N, et al. The biochemical pathway of neurofibrillary degeneration in aging and Alzheimer's disease. *Neurology* 1999; 52: 1158-1165.
28. Flament S, Delacourte A, Verny M, Hauw JJ, Javoy-Agid F. Abnormal Tau proteins in progressive supranuclear palsy. Similarities and differences with the neurofibrillary

- degeneration of the Alzheimer type. *Acta Neuropathol (Berl)* 1991; 81: 591-596.
29. Sergeant N, Wattez A, Delacourte A. Neurofibrillary degeneration in progressive supranuclear palsy and corticobasal degeneration: tau pathologies with exclusively "exon 10" isoforms. *J Neurochem* 1999; 72: 1243-1249.
 30. Steele JC. Progressive supranuclear palsy. Historical notes. *J Neural Transm Suppl* 1994; 42: 3-14.
 31. Litvan I. Diagnosis and management of progressive supranuclear palsy. *Semin Neurol* 2001; 21: 41-48.
 32. Litvan I. Update on progressive supranuclear palsy. *Curr Neurol Neurosci Rep* 2004; 4: 296-302.
 33. Hauw JJ, Verny M, Delaere P, Cervera P, He Y, Duyckaerts C. Constant neurofibrillary changes in the neocortex in progressive supranuclear palsy. Basic differences with Alzheimer's disease and aging. *Neurosci Lett* 1990; 119: 182-186.
 34. Hof PR, Delacourte A, Bouras C. Distribution of cortical neurofibrillary tangles in progressive supranuclear palsy: a quantitative analysis of six cases. *Acta Neuropathol (Berl)* 1992; 84: 45-51.
 35. Bergeron C, Pollanen MS, Weyer L, Lang AE. Cortical degeneration in progressive supranuclear palsy. A comparison with cortical-basal ganglionic degeneration. *J Neuropathol Exp Neurol* 1997; 56: 726-734.
 36. Vermersch P, Robitaille Y, Bernier L, Wattez A, Gauvreau D, Delacourte A. Biochemical mapping of neurofibrillary degeneration in a case of progressive supranuclear palsy: evidence for general cortical involvement. *Acta Neuropathol (Berl)* 1994; 87: 572-577.
 37. Rebeiz JJ, Kolodny EH, Richardson EP, Jr. Corticodentatonigral degeneration with neuronal achromasia. *Arch Neurol* 1968; 18: 20-33.
 38. Rinne JO, Lee MS, Thompson PD, Marsden CD. Corticobasal degeneration. A clinical study of 36 cases. *Brain* 1994; 117 (Pt 5): 1183-1196.
 39. Ikeda K, Akiyama H, Haga C, Kondo H, Arima K, Oda T. Argyrophilic thread-like structure in corticobasal degeneration and supranuclear palsy. *Neurosci Lett* 1994; 174: 157-159.
 40. Litvan I. Progressive supranuclear palsy and corticobasal degeneration. *Baillieres Clin Neurol* 1997; 6: 167-185.
 41. Delacourte A. The molecular parameters of tau pathology. Tau as a killer and a witness. *Adv Exp Med Biol* 2001; 487: 5-19.
 42. Braak H, Braak E. Argyrophilic grain disease: frequency of occurrence in different age categories and neuropathological diagnostic criteria. *J Neural Transm* 1998; 105: 801-819.
 43. Braak H, Braak E. Argyrophilic grains: characteristic pathology of cerebral cortex in cases of adult onset dementia without Alzheimer changes. *Neurosci Lett* 1987; 76: 124-127.
 44. Braak H, Braak E. Cortical and subcortical argyrophilic grains characterize a disease associated with adult onset dementia. *Neuropathol Appl Neurobiol* 1989; 15: 13-26.
 45. Togo T, Sahara N, Yen SH, et al. Argyrophilic grain disease is a sporadic 4-repeat tauopathy. *J Neuropathol Exp Neurol* 2002; 61: 547-556.
 46. Tolnay M, Clavaguera F. Argyrophilic grain disease: a late-onset dementia with distinctive features among tauopathies. *Neuropathology* 2004; 24: 269-283.
 47. Maurage CA, Sergeant N, Schraen-Maschke S, et al. Diffuse form of argyrophilic grain disease: a new variant of four-repeat tauopathy different from limbic argyrophilic grain disease. *Acta Neuropathol (Berl)* 2003; 106: 575-583.
 48. Mattila P, Togo T, Dickson DW. The subthalamic nucleus has neurofibrillary tangles in argyrophilic grain disease and advanced Alzheimer's disease. *Neurosci Lett* 2002; 320: 81-85.
 49. Hutton M. Molecular genetics of chromosome 17 tauopathies. *Ann N Y Acad Sci* 2000; 920: 63-73.
 50. Ishizawa T, Ko LW, Cookson N, Davias P, Espinoza M, Dickson DW. Selective neurofibrillary degeneration of the hippocampal CA2 sector is associated with four-repeat tauopathies. *J Neuropathol Exp Neurol* 2002; 61: 1040-1047.
 51. Miserez AR, Clavaguera F, Monsch AU, Probst A, Tolnay M. Argyrophilic grain disease: molecular genetic difference to other four-repeat tauopathies. *Acta Neuropathol (Berl)* 2003; 106:3 63-366.
 52. Brion S, Plas J, Jeanneau A. [Pick's disease. Anatomico-clinical point of view]. *Rev Neurol (Paris)* 1991; 147: 693-704.
 53. Constantinidis J, Richard J, Tissot R. Pick's disease. Histological and clinical correlations. *Eur Neurol* 1974; 11: 208-217.
 54. Hof PR, Bouras C, Perl DP, Morrison JH. Quantitative neuropathologic analysis of Pick's disease cases: cortical distribution of Pick bodies and coexistence with Alzheimer's disease. *Acta Neuropathol (Berl)* 1994; 87: 115-124.
 55. Buee Scherrer V, Hof PR, Buee L, et al. Hyperphosphorylated tau proteins differentiate corticobasal degeneration and Pick's disease. *Acta Neuropathol (Berl)* 1996; 91: 351-359.
 56. Delacourte A, Robitaille Y, Sergeant N, et al. Specific pathological Tau protein variants characterize Pick's disease. *J Neuropathol Exp Neurol* 1996; 55: 159-168.
 57. Sergeant N, David JP, Lefranc D, Vermersch P, Wattez A, Delacourte A. Different distribution of phosphorylated tau protein isoforms in Alzheimer's and Pick's diseases. *FEBS Lett* 1997; 412: 578-582.
 58. Delacourte A, Sergeant N, Wattez A, Gauvreau D, Robitaille Y. Vulnerable neuronal subsets in Alzheimer's and Pick's disease are distinguished by their tau isoform distribution and phosphorylation. *Ann Neurol* 1998; 43: 193-204.
 59. Probst A, Tolnay M, Langui D, Goedert M, Spillantini MG. Pick's disease: hyperphosphorylated tau protein segregates to the somatoaxonal compartment. *Acta Neuropathol (Berl)* 1996; 92: 588-596.
 60. Mailliot C, Sergeant N, Bussiere T, Caillet-Boudin ML, Delacourte A, Buee L. Phosphorylation of specific sets of tau isoforms reflects different neurofibrillary degeneration processes. *FEBS Lett* 1998; 433: 201-204.
 61. Harper PS, Reardon W. Heart disease in myotonic dystrophy. *Lancet* 1992; 339: 939.
 62. Udd B, Meola G, Krahe R, et al. Report of the 115th ENMC workshop: DM2/PROMM and other myotonic dystrophies. 3rd Workshop, 14-16 February 2003, Naarden, The Netherlands. *Neuromuscul Disord* 2003; 13: 589-596.
 63. Brook JD, McCurrach ME, Harley HG, et al. Molecular basis of myotonic dystrophy: expansion of a trinucleotide (CTG) repeat at the 3' end of a transcript encoding a protein kinase family member. *Cell* 1992; 69: 385.

64. Vermersch P, Sergeant N, Ruchoux MM, et al. Specific tau variants in the brains of patients with myotonic dystrophy. *Neurology* 1996; 47: 711-717.
65. Yoshimura N, Otake M, Igarashi K, Matsunaga M, Takebe K, Kudo H. Topography of Alzheimer's neurofibrillary change distribution in myotonic dystrophy. *Clin Neuropathol* 1990; 9: 234-239.
66. Sergeant N, Sablonniere B, Schraen-Maschke S, et al. Dysregulation of human brain microtubule-associated tau mRNA maturation in myotonic dystrophy type 1. *Hum Mol Genet* 2001; 10: 2143-2155.
67. Seznec H, Agbulut O, Sergeant N, et al. Mice transgenic for the human myotonic dystrophy region with expanded CTG repeats display muscular and brain abnormalities. *Hum Mol Genet* 2001; 10: 2717-2726.
68. Wilhelmsen KC, Lynch T, Pavlou E, Higgins M, Nygaard TG. Localization of disinhibition-dementia-parkinsonism-amyotrophy complex to 17q21-22. *Am J Hum Genet* 1994; 55: 1159-1165.
69. Wijker M, Wszolek ZK, Wolters EC, et al. Localization of the gene for rapidly progressive autosomal dominant parkinsonism and dementia with pallido-ponto-nigral degeneration to chromosome 17q21. *Hum Mol Genet* 1996; 5: 151-154.
70. Bird TD, Wijsman EM, Nochlin D, et al. Chromosome 17 and hereditary dementia: linkage studies in three non-Alzheimer families and kindreds with late-onset FAD. *Neurology* 1997; 48: 949-954.
71. Heutink P, Stevens M, Rizzu P, et al. Hereditary frontotemporal dementia is linked to chromosome 17q21-q22: a genetic and clinicopathological study of three Dutch families. *Ann Neurol* 1997; 41: 150-159.
72. Murrell JR, Koller D, Foroud T, et al. Familial multiple-system tauopathy with presenile dementia is localized to chromosome 17. *Am J Hum Genet* 1997; 61: 1131-1138.
73. Foster NL, Wilhelmsen K, Sima AA, Jones MZ, D'Amato CJ, Gilman S. Frontotemporal dementia and parkinsonism linked to chromosome 17: a consensus conference. Conference Participants. *Ann Neurol* 1997; 41: 706-715.
74. Spillantini MG, Goedert M, Crowther RA, Murrell JR, Farlow MR, Ghetti B. Familial multiple system tauopathy with presenile dementia: a disease with abundant neuronal and glial tau filaments. *Proc Natl Acad Sci U S A* 1997; 94: 4113-4118.
75. Spillantini MG, Bird TD, Ghetti B. Frontotemporal dementia and Parkinsonism linked to chromosome 17: a new group of tauopathies. *Brain Pathol* 1998; 8: 387-402.
76. Hutton M, Lendon CL, Rizzu P, et al. Association of missense and 5'-splice-site mutations in tau with the inherited dementia FTDP-17. *Nature* 1998; 393: 702-705.
77. Grover A, Houlden H, Baker M, et al. 5' splice site mutations in tau associated with the inherited dementia FTDP-17 affect a stem-loop structure that regulates alternative splicing of exon 10. *J Biol Chem* 1999; 274: 15134-15143.
78. Goedert M. Tau gene mutations and their effects. *Mov Disord* 2005; 20 Suppl 12: S45-52.
79. Trojanowski JQ, Lee VM. Pathological tau: a loss of normal function or a gain in toxicity? *Nat Neurosci* 2005; 8: 1136-1137.
80. Klein RL, Lin WL, Dickson DW, et al. Rapid neurofibrillary tangle formation after localized gene transfer of mutated tau. *Am J Pathol* 2004; 164: 347-353.
81. Zhang B, Higuchi M, Yoshiyama Y, et al. Retarded axonal transport of R406W mutant tau in transgenic mice with a neurodegenerative tauopathy. *J Neurosci* 2004; 24: 4657-4667.
82. Ikeda M, Shoji M, Kawarai T, et al. Accumulation of filamentous tau in the cerebral cortex of human tau R406W transgenic mice. *Am J Pathol* 2005; 166: 521-531.
83. Boutajangout A, Authelat M, Blanchard V, et al. Characterisation of cytoskeletal abnormalities in mice transgenic for wild-type human tau and familial Alzheimer's disease mutants of APP and presenilin-1. *Neurobiol Dis* 2004; 15: 47-60.
84. Terwel D, Lasrado R, Snauwaert J, et al. Changed conformation of mutant Tau-P301L underlies the moribund tauopathy, absent in progressive, nonlethal axonopathy of Tau-4R/2N transgenic mice. *J Biol Chem* 2005; 280: 3963-3973.
85. Glenner GG, Wong CW. Alzheimer's disease and Down's syndrome: sharing of a unique cerebrovascular amyloid fibril protein. *Biochem Biophys Res Commun* 1984; 122: 1131-1135.
86. Kang J, Lemaire HG, Unterbeck A, et al. The precursor of Alzheimer's disease amyloid A4 protein resembles a cell-surface receptor. *Nature* 1987; 325: 733-736.
87. Goate A, Chartier-Harlin MC, Mullan M, et al. Segregation of a missense mutation in the amyloid precursor protein gene with familial Alzheimer's disease. *Nature* 1991; 349: 704-706.
88. Mullan M, Crawford F, Axelman K, et al. A pathogenic mutation for probable Alzheimer's disease in the APP gene at the N-terminus of beta-amyloid. *Nat Genet* 1992; 1: 345-347.
89. Hardy JA, Higgins GA. Alzheimer's disease: the amyloid cascade hypothesis. *Science* 1992; 256: 84-185.
90. Sherrington R, Rogaeve EI, Liang Y, et al. Cloning of a gene bearing missense mutations in early-onset familial Alzheimer's disease. *Nature* 1995; 375: 754-760.
91. Duff K, Eckman C, Zehr C, et al. Increased amyloid-beta42(43) in brains of mice expressing mutant presenilin 1. *Nature* 1996; 383: 710-713.
92. Braak H, Braak E. Development of Alzheimer-related neurofibrillary changes in the neocortex inversely recapitulates cortical myelogenesis. *Acta Neuropathol (Berl)* 1996; 92: 197-201.
93. Braak H, Braak E. Neuropathological staging of Alzheimer-related changes. *Acta Neuropathol* 1991; 82: 239-259.
94. Hyman BT, Trojanowski JQ. Consensus recommendations for the postmortem diagnosis of Alzheimer disease from the National Institute on Aging and the Reagan Institute Working Group on diagnostic criteria for the neuropathological assessment of Alzheimer disease. *J Neuropathol Exp Neurol* 1997; 56: 1095-1097.
95. Khachaturian ZS. Diagnosis of Alzheimer's disease. *Arch Neurol* 1985; 42: 1097-1105.
96. Mirra SS, Heyman A, McKeel D, et al. The Consortium to Establish a Registry for Alzheimer's Disease (CERAD). Part II. Standardization of the neuropathologic assessment of Alzheimer's disease. *Neurology* 1991; 41: 479-486.
97. Goedert M, Spillantini MG, Davies SW. Filamentous nerve cell inclusions in neurodegenerative diseases. *Curr Opin Neurobiol* 1998; 8: 619-632.
98. Delacourte A, David JP, Sergeant N, et al. The biochemical pathway of neurofibrillary degeneration in aging and Alzheimer's disease. *Neurology* 1999; 52: 1158-1165.

99. Hartig W, Klein C, Brauer K, et al. Abnormally phosphorylated protein tau in the cortex of aged individuals of various mammalian orders. *Acta Neuropathol (Berl)* 2000; 100: 305-312.
100. Schultz C, Hubbard GB, Rub U, Braak E, Braak H. Age-related progression of tau pathology in brains of baboons. *Neurobiology of Aging* 2000; 21: 905-912.
101. Muraige CA, Sergeant N, Ruchoux MM, Hauw JJ, Delacourte A. Phosphorylated serine 199 of microtubule-associated protein tau is a neuronal epitope abundantly expressed in youth and an early marker of tau pathology. *Acta Neuropathol (Berl)* 2003; 105: 89-97.
102. Delacourte A, Sergeant N, Champain D, et al. Nonoverlapping but synergetic tau and APP pathologies in sporadic Alzheimer's disease. *Neurology* 2002; 59: 398-407.
103. Guillozet AL, Weintraub S, Mash DC, Mesulam MM. Neurofibrillary tangles, amyloid, and memory in aging and mild cognitive impairment. *Arch Neurol* 2003; 60: 729-736.
104. Blennow K. CSF biomarkers for mild cognitive impairment. *J Intern Med* 2004; 256: 224-234.
105. Delacourte A. The biochemical pathway of neurofibrillary degeneration in aging and Alzheimer's disease. *Neurology* 2000; 54: 538.
106. Braak H, Braak E. Frequency of stages of Alzheimer-related lesions in different age categories. *Neurobiol Aging* 1997; 18: 351-357.
107. Sergeant N, Bombois S, Ghestem A, et al. Truncated beta-amyloid peptide species in pre-clinical Alzheimer's disease as new targets for the vaccination approach. *J Neurochem* 2003; 85: 1581-1591.
108. Turner PR, O'Connor K, Tate WP, Abraham WC. Roles of amyloid precursor protein and its fragments in regulating neural activity, plasticity and memory. *Prog Neurobiol* 2003; 70: 1-32.
109. Sergeant N, David JP, Champain D, Ghestem A, Wattez A, Delacourte A. Progressive decrease of amyloid precursor protein carboxy terminal fragments (APP-CTFs), associated with tau pathology stages, in Alzheimer's disease. *J Neurochem* 2002; 81: 663-672.
110. Cao X, Sudhof TC. A transcriptively active complex of APP with Fe65 and histone acetyltransferase tip60. *Science* 2001; 293: 115-120.
111. Cao X, Sudhof TC. Dissection of amyloid-beta precursor protein-dependent transcriptional transactivation. *J Biol Chem* 2004; 279: 24601-24611.
112. Pardossi-Piquard R, Petit A, Kawarai T, et al. Presenilin-dependent transcriptional control of the Abeta-degrading enzyme neprilysin by intracellular domains of betaAPP and APLP. *Neuron* 2005; 46: 541-554.
113. Neve RL, Robakis NK. Alzheimer's disease: a re-examination of the amyloid hypothesis. *Trends Neurosci* 1998; 21: 15-19.
114. Neve RL. A beta may be a planet, but APP is central. *Neurobiology of Aging* 2001; 22: 151-154.
115. Lee HG, Casadesus G, Zhu X, Takeda A, Perry G, Smith MA. Challenging the amyloid cascade hypothesis: senile plaques and amyloid-beta as protective adaptations to Alzheimer disease. *Ann N Y Acad Sci* 2004; 1019: 1-4.
116. Rezaei-Zadeh K, Shytle D, Sun N, et al. Green tea epigallocatechin-3-gallate (EGCG) modulates amyloid precursor protein cleavage and reduces cerebral amyloidosis in Alzheimer transgenic mice. *J Neurosci* 2005; 25: 8807-8814.
117. Hampel H, Buerger K, Zinkowski R, et al. Measurement of phosphorylated tau epitopes in the differential diagnosis of Alzheimer disease: a comparative cerebrospinal fluid study. *Arch Gen Psychiatry* 2004; 61: 95-102.
118. Spillantini MG, Murrell JR, Goedert M, Farlow MR, Klug A, Ghetti B. Mutation in the tau gene in familial multiple system tauopathy with presenile dementia. *Proc Natl Acad Sci U S A* 1998; 95: 7737-7741.
119. Baker M, Litvan I, Houlden H, et al. Association of an extended haplotype in the tau gene with progressive supranuclear palsy. *Hum Mol Genet* 1999; 8: 711-715.
120. Sergeant N, Sablonniere B, Schraen-Maschke S, et al. Dysregulation of human brain microtubule-associated tau mRNA maturation in myotonic dystrophy type 1. *Hum Mol Genet* 2001; 10: 2143-2155.
121. Zhukareva V, Vogelsberg-Ragaglia V, Van Deerlin VM, et al. Loss of brain tau defines novel sporadic and familial tauopathies with frontotemporal dementia. *Ann Neurol* 2001; 49: 165-175.
122. Delacourte A, Sergeant N, Wattez A, et al. Tau aggregation in the hippocampal formation: an ageing or a pathological process? *Exp Gerontol* 2002; 37: 1291-1296.
123. Bhat RV, Budd Haerberlein SL, Avila J. Glycogen synthase kinase 3: a drug target for CNS therapies. *J Neurochem* 2004; 89: 1313-1317.
124. Ahn JS, Musacchio A, Mapelli M, et al. Development of an assay to screen for inhibitors of tau phosphorylation by cdk5. *J Biomol Screen* 2004; 9: 122-131.